

REPORT DOCUMENTATION PAGE

Form Approved
OMB No. 0704-0188

1a. REPORT SECURITY CLASSIFICATION Unclassified			1b. RESTRICTIVE MARKINGS		
2a. SECURITY CLASSIFICATION AUTHORITY			3. DISTRIBUTION / AVAILABILITY OF REPORT Distribution unlimited - approved for public release		
2b. DECLASSIFICATION/DOWNGRADING SCHEDULE			5. MONITORING ORGANIZATION REPORT NUMBER(S)		
4. PERFORMING ORGANIZATION REPORT NUMBER(S)			7a. NAME OF MONITORING ORGANIZATION US Army Medical Research and Development Command		
6a. NAME OF PERFORMING ORGANIZATION US Army Medical Research Institute of Infectious Disease		6b. OFFICE SYMBOL (If applicable) MCMR-UIP-C	7b. ADDRESS (City, State, and ZIP Code) Ft. Detrick Frederick, MD 21702-5012		
6c. ADDRESS (City, State, and ZIP Code) Ft. Detrick Frederick, MD 21702-5011			9. PROCUREMENT INSTRUMENT IDENTIFICATION NUMBER		
8a. NAME OF FUNDING/SPONSORING ORGANIZATION		8b. OFFICE SYMBOL (If applicable)	10. SOURCE OF FUNDING NUMBERS		
8c. ADDRESS (City, State, and ZIP Code)		PROGRAM ELEMENT NO.	PROJECT NO.	TASK NO.	WORK UNIT ACCESSION NO.
11. TITLE (Include Security Classification) LETHAL EXPERIMENTAL INFECTIONS OF RHESUS MONKEYS BY AEROSOLIZED EBOLA VIRUS					
12. PERSONAL AUTHOR(S) E. JOHNSON, N. JAAX, J. WHITE, AND P. JAHRLING					
13a. TYPE OF REPORT		13b. TIME COVERED FROM _____ TO _____		14. DATE OF REPORT (Year, Month, Day) 13 Jan 95	
15. PAGE COUNT 31					
16. SUPPLEMENTARY NOTATION					
17. COSATI CODES			18. SUBJECT TERMS (Continue on reverse if necessary and identify by block number)		
FIELD	GROUP	SUB-GROUP			
19. ABSTRACT (Continue on reverse if necessary and identify by block number) SUMMARY: The potential of aerogenic infection by Ebola virus was established by using a head-only exposure aerosol system. Virus-containing droplets of 0.8-1.2 um were generated and administered into the respiratory tract of rhesus monkeys via inhalation. Inhalation of viral doses as low as 400 plaque-forming units of virus caused a rapidly fatal disease in four to five days. The illness was clinically identical to that reported for parenteral virus inoculation, except for the occurrence of subcutaneous and venipuncture site bleeding and serosanguinous nasal discharge. Immunocytochemistry revealed cell-associated Ebola virus antigens present in airway epithelium, alveolar pneumocytes, and macrophages in the lung and pulmonary lymph nodes; extracellular antigen was present on mucosal surfaces of the nose, oropharynx, and airways. Aggregates of characteristic filamentous virus were present within type I pneumocytes, macrophages, and air spaces of the lung by electron microscopy. Demonstration of fatal aerosol transmission of this virus in monkeys reinforces the importance of taking appropriate precautions to prevent its potential aerosol transmission to humans.					
20. DISTRIBUTION / AVAILABILITY OF ABSTRACT <input type="checkbox"/> UNCLASSIFIED/UNLIMITED <input type="checkbox"/> SAME AS RPT. <input type="checkbox"/> DTIC USERS			21. ABSTRACT SECURITY CLASSIFICATION		
22a. NAME OF RESPONSIBLE INDIVIDUAL			22b. TELEPHONE (Include Area Code)		22c. OFFICE SYMBOL

15 Nov 94

**LETHAL EXPERIMENTAL INFECTIONS OF RHESUS
MONKEYS BY AEROSOLIZED EBOLA VIRUS**

E. Johnson, N. Jaax, J. White, and P. Jahrling

*United States Army Medical Research Institute of
Infectious Diseases, Frederick, Maryland 21702-5011*

APPROVED FOR PUBLIC RELEASE; DISTRIBUTION UNLIMITED
CLEARED 15 DEC 94

Accession For	
NTIS CRA&I	<input checked="" type="checkbox"/>
DTIC TAB	<input type="checkbox"/>
Unannounced	<input type="checkbox"/>
Justification	
By	
Distribution /	
Availability Codes	
Dist	Avail and / or Special
A-1	

19950322 094

Summary

The potential of aerogenic infection by Ebola virus was established by using a head-only exposure aerosol system. Virus-containing droplets of 0.8-1.2 μm were generated and administered into the respiratory tract of rhesus monkeys via inhalation. Inhalation of viral doses as low as 400 plaque-forming units of virus caused a rapidly fatal disease in four to five days. The illness was clinically identical to that reported for parenteral virus inoculation, except for the occurrence of subcutaneous and venipuncture site bleeding and serosanguinous nasal discharge. Immunocytochemistry revealed cell-associated Ebola virus antigens present in airway epithelium, alveolar pneumocytes, and macrophages in the lung and pulmonary lymph nodes; extracellular antigen was present on mucosal surfaces of the nose, oropharynx, and airways. Aggregates of characteristic filamentous virus were present within type I pneumocytes, macrophages, and air spaces of the lung by electron microscopy. Demonstration of fatal aerosol transmission of this virus in monkeys reinforces the importance of taking appropriate precautions to prevent its potential aerosol transmission to humans.

Introduction

The African filoviruses, Ebola virus and Marburg virus, are deadly pathogens in primates, yet their ecology and epidemiology are largely unknown. (Martini et al. 1968; Bremen et al. 1976) The environmental conditions that influence viral transmission from unknown reservoir species to humans are undefined. These viruses are thought to circulate undetected within unknown reservoir species in sub-saharan Africa, presumably as enzootic infections, until changing ecologic conditions lead to human infections. In humans, these pathogens cause sporadic, but dramatic, outbreaks of lethal hemorrhagic disease with case fatality rates ranging from 30 to 90% (Martini, Knouff et al. 1968; Gear et al. 1975; Francis et al. 1978; Smith et al. 1978; Smith et al. 1982).

The route of infection for natural human exposures can only be inferred from extremely limited epidemiological investigations conducted during the rare periods of viral activity in human populations (Bremen, Piot et al. 1976). Frequently, human to human transmission appears to be caused by direct contact with infectious blood or body fluids. In humans, the highest virus concentrations are

found in blood; lower levels are present in throat washings and urine (WHO 1978b; WHO 1978a; Peters et al. 1990). Presumably, the virus invades the body through the conjunctiva, gastrointestinal tract, or breaks in the skin. Experimental confirmation of parenteral inoculation as a transmission mechanism has been established by studies of nonhuman primates (Baskerville et al. 1978; Bowen et al. 1978; Fisher-Hoch et al. 1985). Limited experimental and epidemiological data suggest that aerosol transmission of filoviruses from monkey to monkey or from monkey to human may also occur. In an outbreak of Ebola (Reston) within a U.S. quarantine facility, the virus readily spread within animal rooms. While infections in adjacent cages may have occurred by droplet contact, infections in distant cages suggests aerosol transmission, as evidence of direct physical contact with an infected source could not be established (Dalgard et al. 1992). The prominent pneumonic component of the disease in infected monkeys supports this conclusion (Geisbert 1992), as does a serosurvey of human contacts. Six animal-care workers in close daily contact with infected monkeys were seropositive by indirect immunofluorescent antibody assay (IFA) (CDC 1990). Of the six, five had no known history of parenteral or trauma-induced exposure to Ebola virus,

which suggested the possibility of aerosol transmission. Numerous Marburg disease cases occurred in laboratory workers who wore gloves while handling infected monkey tissues and/or were without visible wounds when admitted to Marburg University Medical Clinic in 1967 (Martini 1971). Experimental transmission of Marburg virus between monkeys whose only contact was by a nose-to-nose apparatus has also been reported (Pokhodyaev et al. 1991). Despite this circumstantial evidence for aerosol spread of filoviruses, there has been no previous experimental confirmation of their aerosol transmission.

This paper reports aerosol transmission of Ebola virus to rhesus monkeys. The pathophysiological events and histopathological lesions associated with Ebola virus infections after aerosol exposures are described.

MATERIAL AND METHODS

Biologic containment

Infectious material and animals were handled within the maximum containment (biological safety level 4) facilities at the United States Army Medical Research Institute of Infectious Diseases, Frederick, MD. Laboratory personnel wore positive-pressure protective suits (ILC, Dover, Federica, Delaware) supplied with umbilical-fed, HEPA-filtered air.

Virus cultures and infectivity assays

Virus was propagated in Vero cells grown in Eagle's minimum essential medium (EMEM) supplemented with 10% heat inactivated fetal bovine serum, antibiotics (100 U of penicillin and 100 μ g of streptomycin sulfate per ml), and 2 mM L-glutamine. Stocks of Ebola virus (Zaire type) were prepared as clarified, infected cell-culture fluids, passage level 4, and stored at -70°C. Viral titers were determined by plaque assay (Moe et al. 1981). The stocks routinely contained 6 to 7 log₁₀ plaque-forming units (PFU) of infectious virus per ml.

Study design

Six rhesus monkeys (*Macaca mulatta*) were used to evaluate the aerosol infectivity of Ebola virus (Zaire). Rhesus monkeys were selected for aerosol exposure to Ebola virus because this species was previously used to define pathological changes following parenterally induced filovirus infections (Baskerville, Bowen et al. 1978; Bowen, Platt et al. 1978; Fisher-Hoch, Platt et al. 1985). All animals were seronegative for filovirus-reactive antibody before Ebola virus aerosol challenge.

The monkeys were housed individually in stainless steel cages. Monkeys were given water ad libitum and fed twice daily with Purina monkey chow supplemented with fresh fruit. The animals were randomly assigned to one of three aerosol-exposure groups of two animals each. Group one (monkeys 1465 and R280) was exposed to a low inhaled dose ($2.6 \log_{10}$) of Ebola virus, group two (B64 and B65) was exposed to a high dose ($4.7 \log_{10}$ PFUs) of Ebola virus, and group three (control group, 121N and 556 A) was exposed to aerosolized, uninfected cell culture fluid.

All monkeys were checked daily for clinical signs of illness. Monkeys were anesthetized with intramuscular ketamine HCl (5mg/kg), and sterile femoral venous blood samples were collected on days 4, 7, and terminally for clinical chemistry and hematological evaluations. Values were compared with results obtained from samples drawn before exposure.

Aerosol exposure

Monkeys were anesthetized with Ketamine HCL (5 mg/kg) for the aerosol exposure phase of the experiment. While anesthetized, each monkey was placed in dorsal recumbency

with its head extending through a rubber dam (designed to fit snugly around the neck without restricting ventilation) into a 8000-cm³ exposure box. The monkey was placed in a gas-tight, environment-controlled Hazelton chamber (24°C and <40% relative humidity) that contained a modified Henderson apparatus and a Collision nebulizer (Henderson 1952). The nebulizer, driven by compressed air at 20 PSI, generated an aerosol flow rate of 16.5 liters/min. and disseminated the 25 ml test solution at 0.35 ml/minute. The median mass diameter of the generated aerosol particles ranged from 0.8 to 1.5 µm. The aerosol was mixed automatically with a secondary 8.5 liters/min. air supply and circulated through the exposure box. The aerosol challenge dose was determined by a mid-exposure sample collected in an all-glass impinger calibrated to sample at a rate of 12.5 liters/min. The aerosol specimen was impinged in supplemented EMEM containing an antifoam emulsion. After a 10 minute exposure, the Hazelton chamber was flushed with clean air and the virus-contaminated contents exhausted through double HEPA filters. The head and neck of the exposed animal were decontaminated with 1.0 % sodium hypochlorite and the monkey was placed in its cage. The viral titer per ml of impinger fluid was determined by plaque assay. The

exposure dose was calculated by multiplying the virus plaque-forming units (PFU) per liter of aerosol, the exposure period in minutes, and respiratory volume (liters/min). Respiratory volume was determined on the basis of body weight and Guyton's formula (Guyton 1947).

Hematology, serum enzyme and coagulation assays

Total and differential white blood cells (WBC) were counted by using a laser-based hematological analyzer. Leukocyte differentials were confirmed manually on a Wright-stained blood smear. Platelets were counted with a Coulter Model ZBI particle counter. Lactic acid dehydrogenase (LDH), serum alanine aminotransferase (ALT), blood urea nitrogen (BUN), creatinine (CRE), alkaline phosphatase (ALP), and creatinine phosphokinase (CK) levels were measured with a Multi Stat III Plus chemical analyzer.

Histopathology and immunocytochemistry examination

Complete necropsies were performed on all virus-exposed animals. One monkey (1465) died on day 8 post-exposure and was necropsied immediately. The other three monkeys (B54, B65, and R280) were humanely killed when they became moribund on days 7, 8, and 9 post-exposure, respectively.

They were exsanguinated while deeply anesthetized with intravenous sodium pentobarbital, and perfused with a universal fixative (neutral phosphate-buffered 4.0% paraformaldehyde containing 1.0% glutaraldehyde) for light and ultrastructural microscopy. Representative tissue specimens from the non-perfused animal that died naturally were selected and immersion-fixed in 10% neutral buffered formalin. The tissues were processed and embedded in paraffin according to established procedures (Prophet et al. 1992). Histology sections were cut at 5-6 μm on a rotary microtome, mounted on glass slides, and stained with Harris's hematoxylin and eosin in a Stainomatic specimen stainer. Phosphotungstic acid hematoxylin (PTAH) stain was used to detect fibrin deposits (Prophet, Arrington et al. 1992). For immunohistochemical staining, the paraffin-embedded tissues were sectioned at 5 μm and mounted on silane-coated glass slides. After deparaffinization and hydration, the sections were digested with protease and treated with Ebola virus reactive monoclonal antibodies (AE11, 8A11 and B11) prepared from hybridoma cells provided under contract by the Centers for Disease Control, Atlanta, Georgia. Biotinylated horse anti-mouse immunoglobulin was reacted with the bound monoclonal antibody, and the reactive

product visualized by an alkaline phosphatase-labelled streptavidin method (Jahrling et al. 1990). Archived necropsy material previously collected from fatal monkey infections induced by low doses (1-10 PFU) of parenterally inoculated Ebola virus (Zaire strain) and Marburg virus (Musoki strain) were processed in parallel to serve as positive and negative controls, respectively, for Ebola virus antigen.

Electron microscopy

Tissues were fixed in universal fixative and sliced into 1-mm cubes, washed three times in phosphate buffer, and post-fixed in phosphate-buffered 1.0% osmium tetroxide. The fixed tissues were washed in distilled water, stained en block in 1.0% uranyl acetate, dehydrated, and embedded in Epon 812. Ultrathin sections, cut on an LKB Ultratome, were stained with uranyl acetate and lead citrate and examined in a Jeol 100 CX electron microscope at 80 KV.

Results

Clinical disease

Clinical disease occurred in all four Ebola virus-

exposed monkeys, but not either of the control monkeys. The clinical disease in the aerosol-challenged monkeys was similar to the syndrome previously described in parenterally inoculated rhesus monkeys (Baskerville, Bowen et al. 1978; Bowen, Platt et al. 1978; Fisher-Hoch, Platt et al. 1985). However, we observed serosanguinous nasal discharge, subcutaneous hemorrhage, and prolonged bleeding after venipuncture in these aerosol-infected monkeys, which was not reported in previous studies (Baskerville, Bowen et al. 1978; Bowen, Platt et al. 1978; Fisher-Hoch, Platt et al. 1985). The monkeys remained active and clinically normal until the onset of fever (39.9 to 40.2°C) between 4 and 6 days post-exposure. The fever was accompanied by anorexia, lethargy, and development of a cutaneous rash involving the face, trunk, and proximal limbs. One high-dose animal (1465) died within 3 days of the onset of clinical signs (8 days postexposure). The other three were humanely killed when they became moribund on days 7, 8, and 9 post-exposure.

Hematological parameters were altered in three of four Ebola virus-exposed rhesus monkeys (**Figure 1**). The three animals developed a leukocytosis with peak white blood cell counts of 10,300 to 15,200 cells/mm³ on day 4 post-exposure. The leukocytosis was due to an absolute

neutrophilia that ranged from 9,400 to 12,400 granulocytes per mm^3 , which is consistent with other reports (Fisher-Hoch et al. 1983; Fisher-Hoch, Platt et al. 1985). There was a concomitant absolute lymphopenia. The mean platelet count fell from a pre-exposure level of 288×10^3 per mm^3 to 124×10^3 per mm^3 day 7 post-exposure.

Clinically significant elevated clinical chemistry values were observed in all four monkeys after Ebola virus aerosol exposure. All biochemistry parameters measured were normal on day 4 post-exposure. On day 7 post-exposure, 11 to 16-fold increases in LDH levels, accompanied by a 5-fold increase in ALT, were present in all animals (**Figure 2**). Terminal values of ALP and CK were markedly elevated. CRE and BUN levels were only mildly elevated in the infected animals on day 7 post-exposure. Near death, however, these levels were markedly elevated.

Histopathology

Lungs and pulmonary lymph nodes

All Ebola virus aerosol-exposed monkeys had a mild to moderate, patchy, interstitial pneumonia, clearly oriented around terminal bronchioles (bronchocentric pattern).

Additional pulmonary lesions included diffuse leukocytosis, vasculitis, multifocal septal necrosis, thrombosis, hemorrhage, edema, and increased numbers of alveolar macrophages. Large, amorphous, pleomorphic, acidophilic intracytoplasmic inclusions of 5 to 20 μ m were present in circulating and alveolar macrophages of the lungs. With the exception of the bronchocentric pattern evident in this study, all lesions were consistent with those described in previously published reports (Baskerville, Bowen et al. 1978; Bowen, Platt et al. 1978); the bronchocentric pattern was consistent with an inhalation mode of infection. When examined by immunocytochemistry, the strongest viral antigen reactivity in the lungs of aerosol-exposed monkeys also occurred in a bronchocentric pattern, with the heaviest antigen concentration occurring adjacent to terminal bronchioles. Bronchial and bronchiolar epithelium, alveolar pneumocytes, and alveolar macrophages showed positive Ebola virus antigen staining (**Figure 3**). Copious extracellular Ebola virus antigen was also present in secretions on the mucosal surfaces of the nose, oropharynx and airways. Severe lymphoid depletion, necrosis, vasculitis, thrombosis, and variable degrees of hemorrhage, from mild to severe, were present in the

tracheobronchial (TBL) lymph nodes of aerosol-exposed monkeys; intracytoplasmic inclusions were present in circulating and fixed macrophages. The lesions in the TBL nodes were consistent with mesenteric lymph node lesions reported in other studies (Baskerville, Bowen et al. 1978; Bowen, Platt et al. 1978). Immunocytochemical staining of tracheobronchial lymph nodes of aerosol infected monkeys revealed copious extracellular and intracellular (within macrophages) Ebola virus antigen accumulation.

Extrapulmonary lesions in these aerosol-exposed monkeys did not differ significantly from those previously reported (Baskerville, Bowen et al. 1978; Bowen, Platt et al. 1978). The principal extrapulmonary histological lesions were mild to moderate randomly patterned necrosis in the liver, pancreas, intestines, adrenal gland, and bone marrow; moderate to severe necrosis of both the red and white pulp of the spleen, mesenteric, peripheral lymph nodes, and gut-associated lymphoid tissue (GALT); and fibrin deposition and thrombi throughout the vascular system in all organs. Large, amorphous, pleomorphic, acidophilic intracytoplasmic inclusions of 5 to 20 μ m were present in circulating macrophages of various organs, hepatocytes, and adrenocortical cells, as well as the previously described locations.

A detailed immunohistochemical examination of extrapulmonary necropsy tissues was performed and will be addressed in a separate publication. Briefly, copious extracellular and intracellular Ebola virus antigen was present in the liver, adrenal gland, bone marrow, spleen, testes, and kidney. Large antigen deposits were also present in phagocytic cells (such as Kupffer cells and splenic macrophages), cellular thrombi and inflammatory foci.

The presence of virions in the tissues of aerosol-infected monkeys was confirmed by electron microscopy. Extracellular filamentous virions were abundant, and were present in lung alveoli (**Figure 4**), the interstitium of parenchymal organs, the space of Disse and bile canaliculi of the liver, and associated with fibrin thrombi in numerous organs. Type 1 alveolar pneumocytes contained nucleocapsid inclusions with characteristic viral particles budding through plasma membranes into the air space (**Figure 5**). Nucleocapsid inclusions and budding viral particles were also seen in mononuclear cells within the interstitial component of the adrenal glands, spleen, and lymph nodes; alveolar septa and alveolar macrophages of the lungs; and in hepatocytes.

Discussion

^This study demonstrates aerosol transmission of Ebola virus to nonhuman primates. Inhalation doses as low as 400 PFU of virus caused a fatal illness clinically similar to that previously reported for monkeys infected by parenteral inoculation (Baskerville, Bowen et al. 1978; Bowen, Platt et al. 1978; Fisher-Hoch, Platt et al. 1985). The illness was characterized by fever, anorexia, and a petechial rash. Fibrin deposition and fibrin thrombi throughout the vascular system in all monkeys suggested that disseminated intravascular coagulation (DIC) may have also played a role in the clinical manifestations of Ebola virus infection.

Our aerosol infectivity findings for Ebola virus support Dalgard's and Pokhodyaev's observations that suggested a role for aerosol transmission of filoviruses in monkeys. Epidemiology studies of human disease outbreaks in sub-saharan Africa did not suggest that aerosol transmission of filoviruses was likely in that setting. Virus did not spread easily from person to person during the Ebola virus epidemics in Africa, and attack rates were highest in individuals who were in direct physical contact with a primary case (Bres 1978). The rates were 3.5 times higher in people who provided

nursing care than those who were in casual contact with a primary case, and no cases occurred in children whose only known exposure to the virus was sleeping in the huts occupied by their fatally ill parents. Although coughing was common among the human Ebola hemorrhagic fever cases in Africa, there was no direct evidence for aerogenic spread of Ebola virus in human populations. Several potential explanations might account for this situation. It is possible that the quantity and distribution of virus within most patients' respiratory tracts may have been below the level needed to establish effective aerosol transmission. This possibility is supported by histologic examination of archived tissues from one human reference case of Marburg on file in this institute; examination by immunocytochemistry and electron microscopy revealed no positive Marburg viral antigen staining or any ultrastructural evidence of virus in the lung tissue of that case (personal communication, Jaax). We also demonstrated aerosol transmission of Ebola virus at lower temperature and humidity than that normally present in sub-Saharan Africa. Ebola virus sensitivity to the high temperatures and humidity in the thatched, mud, and wadel wattle (?) huts shared by infected family members in southern Sudan (spelling) and northern Zaire may have been a factor limiting aerosol

transmission of Ebola virus in the African epidemics. Both elevated temperature and relative humidity (RH) have been shown to reduce the aerosol stability of viruses (Songer 1967). Our experiments were conducted at 24°C and <40% RH, conditions which are known to favor the aerosol stability of at least two other African hemorrhagic fever viruses, Rift Valley fever and Lassa (Stephenson et al. 1984; Anderson et al. 1991). If the same holds true for filoviruses, aerosol transmission is a greater threat in modern hospital or laboratory settings than it is in the natural climatic ranges of viruses. The route of infection or the degree of pulmonary involvement of the primary cases may also be an important factor to consider when evaluating the natural aerosol transmissibility of the filoviruses. While both parenteral and aerosol exposure to Ebola virus cause a systemic disease involving all organs, monkeys exposed to viral aerosols during our study developed strong immunoreactivity for Ebola virus antigen in airway epithelium, in oral and nasal secretions, and in bronchial and tracheobronchial lymphoid tissue. By electron microscopy, viral replication after aerosol exposure occurred in the lungs and tracheobronchial lymph nodes, and extracellular virus accumulated in alveoli of the lung. Copious extracellular Ebola virus antigen was

present in secretions on the mucosal surfaces of the nose, oral cavity, and pulmonary airways of aerosol-exposed monkeys; strong evidence to support the potential for secondary spread of Ebola virus by aerosol. As previously stated, aerosol spread was implicated in the spread of disease among the monkeys at Reston (Dalgard, Hardy et al. 1992; Geisbert 1992), and may have occurred between monkeys and animal handlers who were in close contact with infected monkeys (CDC 1990). Finally, host sensitivity to space filovirus infections may also be a significant factor influencing the degree of aerosol transmissibility. Asian (*Macaca fascicularis*) and African (*Cercopithecus aethiops*) monkeys are known to be disseminating hosts for filoviruses (Gear, Cassel et al. 1975; CDC 1990). Virus replicates extensively in Ebola virus infected non-human primates, reaching high concentrations in tissues (consistently greater than $6 \log_{10}/g$ of tissue or serum for Reston virus; Jahrling, manuscript in preparation). Quantitative data for viremia levels in humans are lacking, as are estimates of minimal infectious aerosol doses. Certainly, filoviruses have infected humans with no known history of parenteral or ocular inoculation of the virus (Martini 1971; CDC 1990), and a respiratory route of infection cannot be ruled out (Simpson 1977). Those cases

may have resulted from exposures to unusual concentrations of aerosolized virus not often encountered naturally.

Regardless, we have shown that Ebola virus (Zaire strain) can be transmitted by aerosol in an experimental primate model. In light of the pathogenicity of human filovirus infections, health care personnel at risk of exposure should use precautions to minimize the risk of aerosol exposure while managing acutely ill hemorrhagic fever cases of unknown or filoviral etiology. The risk can be markedly reduced by adhering to sound and practical infectious disease management procedures. This requires curtailing aerosol-generating procedures; using protective clothing, including gloves and masks; adequately decontaminating potentially infectious material; and conducting virus diagnostic procedures in regional containment facilities capable of safely handling highly hazardous infectious agents (Comperts et al. 1978; CDC 1988).

▲ Figure 1. Hematological values in Ebola virus aerosol-exposed rhesus monkeys.

Figure 2. Blood chemistry values in Ebola virus aerosol-exposed rhesus monkeys.

▲ Figure 3. Lung from an Ebola virus aerosol-exposed rhesus monkey stained with a mixture of Ebola virus reactive monoclonal antibodies. Antigen reactivity occurred in a bronchocentric pattern oriented around terminal bronchioles. Associated pulmonary macrophages were also positively stained. Magnification 100X

List of Abbreviations and symbols for figures 4 and 5:

AS Alveolar Sac
Cp Capillary
En Endothelial cell
Ep I Epithelial Cell, Type I
Ep II Epithelial Cell, Type II
IS Interstitial space
V Mature virions
* Basal lamina

Figure 4. Extracellular virions(V) in the alveolar sac (AS) and in an interstitial space(IS) between epithelial cells (Ep) and the basal lamina. Note the viral nucleocapsids in the cytoplasm of epithelial cells (single arrow) and a portion of a septal cell (double arrow). Magnification X 15,000.

Figure 5. Note extracellular virions(V) in alveolar sac (AS). A large cytoplasmic inclusion (double arrow) containing viral nucleocapsids in a type I epithelial cell (Ep). Nucleocapsid filaments (single arrow) are also seen in the cytoplasm of the epithelial cell that extends over a type II pneumocyte. Magnification X 30,000.

Anderson, G. W., Lee, J. O., Anderson, A. O., Powell, N., Magniafico, J. A. and Meadors, G. (1991). "Efficacy of a Rift Valley Fever virus vaccine against aerosol infection in rats." *Vaccine* 9, 710-714.

Baskerville, A., Bowen, E. T. W., Platt, G. S., Mcardell and Simpson, D. I. H. (1978). "The pathology of experimental Ebola virus infection in monkeys." *J Path* 125, 131-138.

Bowen, E. T. W., Platt, G. S., Simpson, D. I. H. and McArdell, L. B. (1978). "Ebola hemorrhagic fever: Experimental infection of monkeys." *Trans R Soc Trop Med Hyg* 72, 188-191.

Bremen, J. G., Piot, P., Johnson, K. M., White, M. K., Mbuyi, M., Sureau, P., Heyman, D. L., Van Nieuwenhove, S., McCormick, J. B., Ruppel, J. P., Kintoki, V., Isaacson,

M., Van der Groen, G., Webb, P. A. and Ngvette, K. (1976). The epidemiology of Ebola hemorrhagic fever in Zaire. In: *Ebola Virus Hemorrhagic Fever*, New York, Elsevier/North-Hallond Biomedical Press. 103-122.

Bres, P. (1978). "The epidemic of Ebola haemorrhagic fever in Sudan and Zaire, 1976: An introductory note." *Bull WHO* 56, 245-270.

CDC (1988). "Management of patients with suspected viral hemorrhagic fever." *MMWR* 37, 1-16.

CDC (1990). "Update: Filovirus infections among persons with occupational exposure to nonhuman primates." *MMWR* 39, 266-267.

Comperts, E. D., Isaacson, M., Koorhof, H. J., Mitz, J., Gear, J. H. S., Schouk, B. D., McIntosh, B. and and Prozesky, O. W. (1978). "Handling of highly infectious material in a clinical pathology laboratory and in a viral diagnostic unit." *S Afr Med J* 53, 243-248.

Dalgard, D. W., Hardy, R. J., Pearson, S. L., Pucak, G. J., Quander, R. V., Zack, P. M., Peters, C. J. and

Jahrling, P. B. (1992). "Combined simian hemorrhagic fever and Ebola virus infection in cynomolgus monkeys." *Lab An Sci* 42, 152-7.

Fisher-Hoch, S. P., Lloyd, G., Platt, G. S., Simpson, D. I. H., Wild, G. H. and Barrett, A. J. (1983).

"Hematological and biochemical monitoring of Ebola infection in rhesus monkeys: Implications for patient management." *Lancet* 1055-1058.

Fisher-Hoch, S. P., Platt, G. S., Neild, G. H., Southee, T., Baskerville, A., Raymond, R. T., Lloyd, G. and Simpson, D. I. H. (1985). "Pathophysiology of shock and hemorrhage in a fulminating viral infection." *J Infect Dis* 152, 887-94.

Francis, D. P., Smith, D. H., Highton, R. B., Simpson, D. I. H., Lolik, P., Deng, I. M., Gillo, A. L., Idris, A. A. and Tahir, B. E. (1978). Ebola fever in the Sudan 1976: epidemiological aspects of the disease. In: *Ebola Virus Hemorrhagic Fever*, New York, Elsevier/North-Holland Biomedical Press. 129-136.

Gear, J. S. S., Cassel, G. A., Gear, A. J., Trappler, B.,

Clausen, L., Meyers, A. M., Kew, K. C., Bothwell, T. H., Sher, R., Miller, G. B., Schneider, J., Koomhof, H. J., Compets, E. D., Isaacson, M. and Gear, J. H. S. (1975). "Outbreak of Marburg virus disease in Johannesburg." *Br Med J* 4, 489-493.

Geisbert, T. W. (1992). "Association of Ebola related Reston virus particles and antigen with tissue lesions of monkeys imported to the United States." *J Comp Path* 106, 137-52.

Guyton, A. C. (1947). "Measurement of the respiratory volumes of laboratory animals." *Amer J Phys* 150, 70-77.

Henderson, D. H. (1952). "An apparatus for the study of airborne infection." *J Hyg* 50, 53-68.

Jahrling, P. B., Geisbert, T. W., Dalgard, D. W., Johnson, E. D., Ksiazek, T. G., Hall, W. C. and Peters, C. J. (1990). "Preliminary report: Isolation of Ebola virus from monkeys imported to USA." *Lancet* 335, 502-5.

Martini, G. A. (1971). *Marburg virus disease: Clinical syndrome*. New York, Springer Verlag.

Martini, G. A., Knouff, H. G., Schmidt, H. A., Mayer, G. and Baltzer, G. (1968). "A hitherto unknown infectious disease contracted from monkeys." *German Med Month* 13, 457-470.

Moe, J. B., Lambert, R. D. and Lupton, L. W. (1981). "Plaque assay of Ebola virus." *J Clin Micro* 13, 791-793.

Peters, C. J., Johnson, E. D. and McKee, K. T. (1990). Filoviruses and management of viral hemorrhagic fevers. In: *The Textbook of Human Virology*, St. Louis, Mosby.

Pokhodyaev, V. A., Gonchar, N. I. and Pshenichov, V. A. (1991). "Experimental study of Marburg virus contact transmission." *Vopro Vir* 36, 506-508.

Prophet, E. B., Arrington, J. B. and Subin, L. H., Ed. (1992). Laboratory methods in histotechnology. Armed Forces Institute of Pathology.

Simpson, D. I. H. (1977). Marburg and Ebola virus infections: A guide for their diagnosis, management, and control. World Health Organization.

Smith, D. H., Francis, D., Simpson, D. I. H. and Highton, R. B. (1978). The Nzara outbreak of viral hemorrhagic fever. In: *Ebola virus hemorrhagic fever*, New York, Elsevier/North Hallond Biomedical Press.

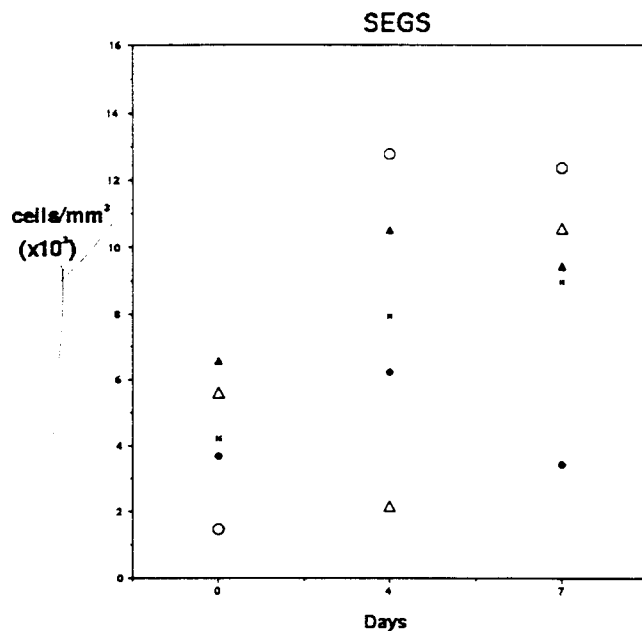
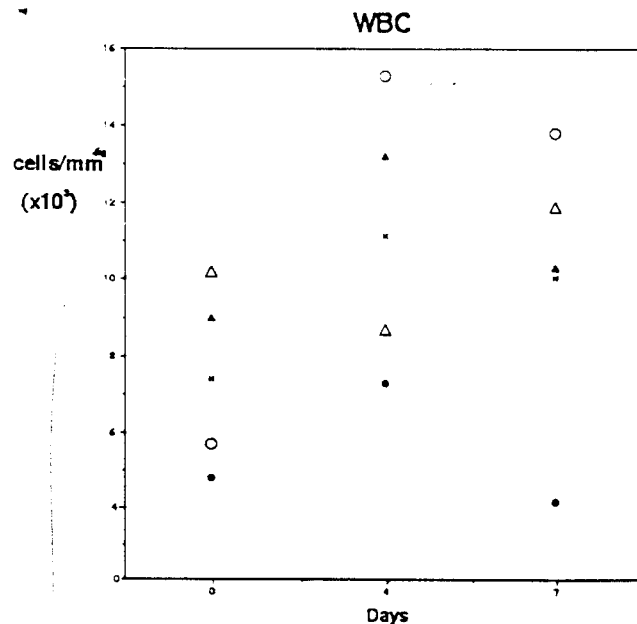
Smith, D. H., Isaacson, M., Johnson, K. M., Bagshowe, A., Johnson, B. K., Swanapoel, R., Kiley, M., Scanjok, T. and Koinage, K. (1982). "Marburg virus disease in Kenya." *Lancet* 1, 816-820.

Songer, J. R. (1967). "Influence of relative humidity on the survival of some airborne viruses." *Appl Microbiol* 15, 35-42.

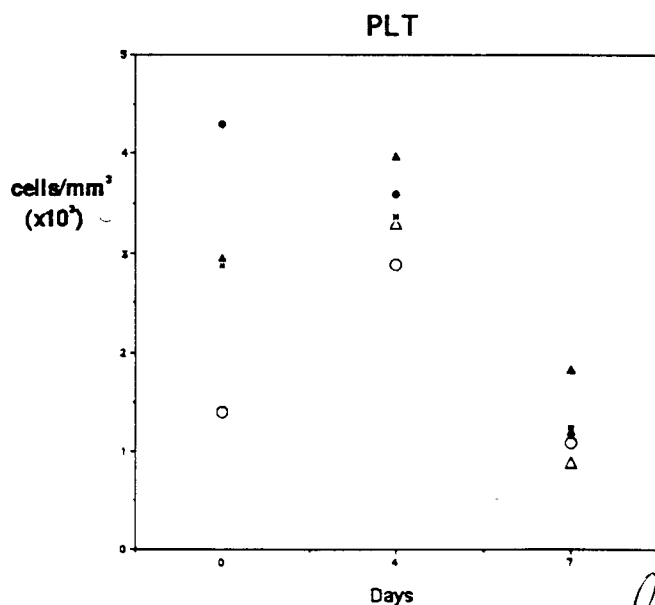
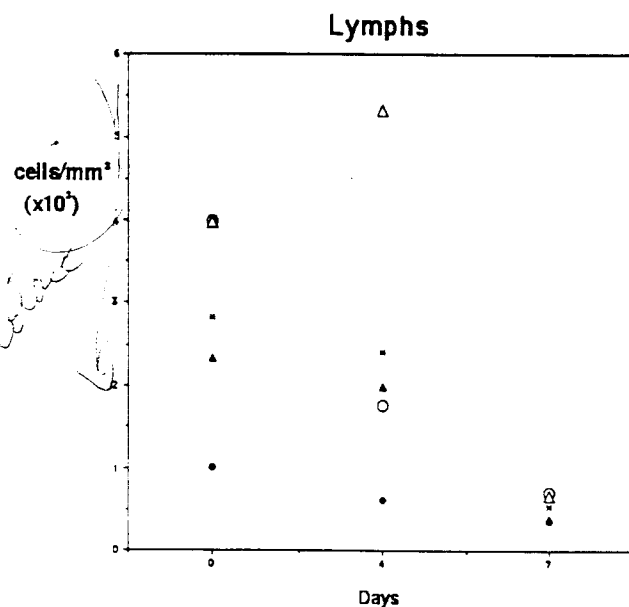
Stephenson, E. H., Larson, J. W. and Dominik, J. W. (1984). "Effect of environmental factors on aerosol-induced Lassa virus infection." *J Med Virol* 14, 295-303.

WHO (1978a). "Ebola haemorrhagic fever in Sudan." *Bull WHO* 56, 247-270.

WHO (1978b). "Ebola haemorrhagic fever in Zaire, 1976." *Bull WHO* 56, 271-293.



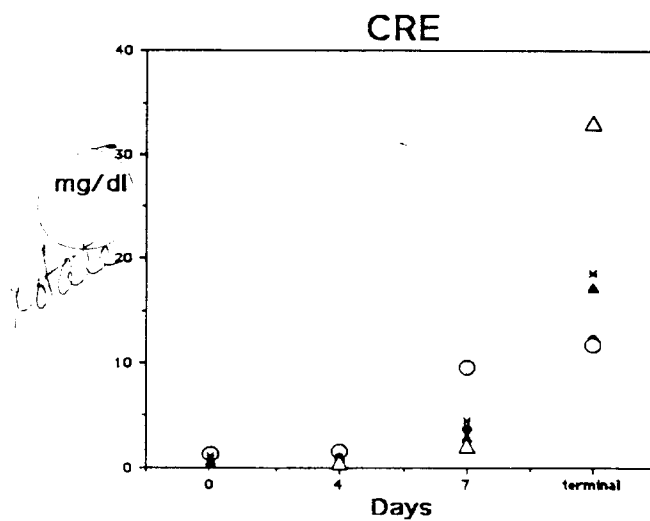
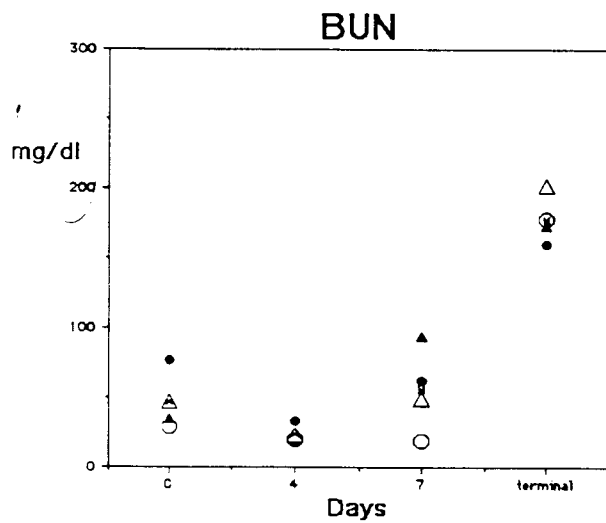
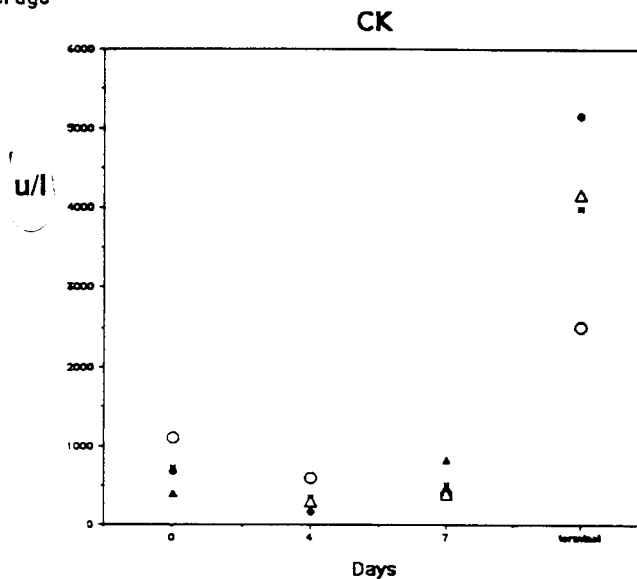
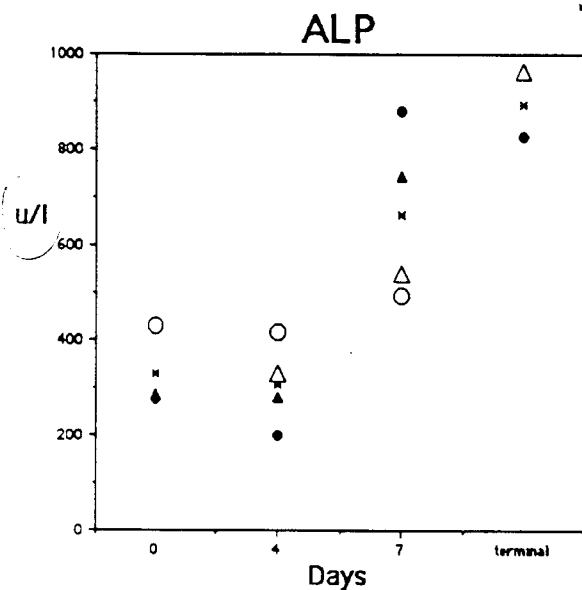
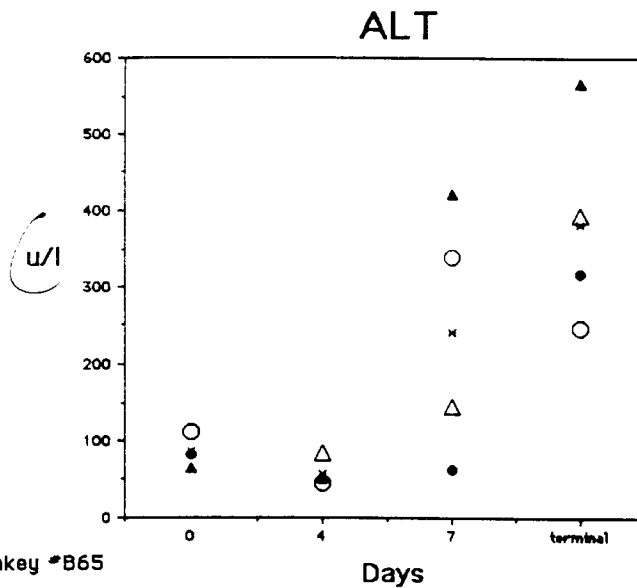
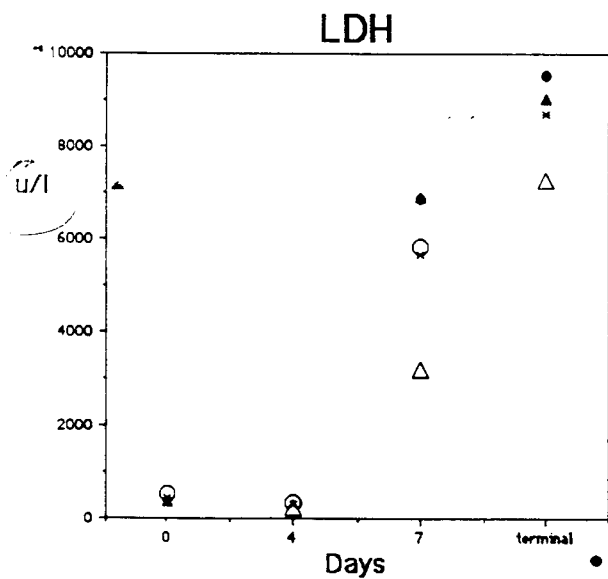
- Monkey #B65
- Monkey #B54
- ▲ Monkey #1465
- △ Monkey #R280
- × Average



font of the
figures are
at least like
12-pt courier,
to withstand
reduction.

please note -
these are reduced -
originals are
larger.

Fig 1



larger fonts Fig 2

Fig 3

